



ELSEVIER

INTERNATIONAL
JOURNAL OF SURGERYjournal homepage: www.int-journal-surgery.com

LETTER TO THE EDITOR

A stitch in time did not save *nine* – Because “it was not my field”

Dear Editor

An ileostomy site can sometimes bleed but this is usually minor.¹ As the surgical team on call, we were asked to come urgently and see a 77-year-old lady who was admitted for routine haemodialysis on a renal ward. She had end-stage renal failure due to diabetic nephropathy. She was bleeding profusely from her ileostomy that was performed 3 years ago.

When we arrived, her blood pressure was 30 mm Hg systolic. The patient was being intubated and the medical registrar was telling her nephrology consultant “we are losing her”. She had already been transfused *nine* units of blood, platelets and fresh frozen plasma. There was no haematemesis. As soon as we removed the ileostomy bag a jet of blood gushed from an artery at the bridge of the loop ileostomy. The yellow stools at the proximal lumen (wiped off before the photograph was taken) confirmed that there was no proximal bleeding. The artery was compressed between the thumb and index finger and then with the McGill forceps until the theatre nurse arrived with instruments. The artery was under-run (see Fig. 1) with a 2-0 Vicryl suture. With the outflow sealed, the blood pressure recovered and the patient’s life was saved.

Such torrential bleeding is rare, but the event demonstrates the fragility of today’s overspecialised system of medicine. If only someone had opened the ileostomy bag earlier the whole saga could have been avoided – but an ileostomy is not a medical ward’s speciality. So it was left to the ‘specialists’ to examine it! In these times of sub-sub specialisation we must not forget the immense potential of human abilities. Let us not cut-off the rest of our wings lest we collapse mid-flight when the single specialist feather fails.

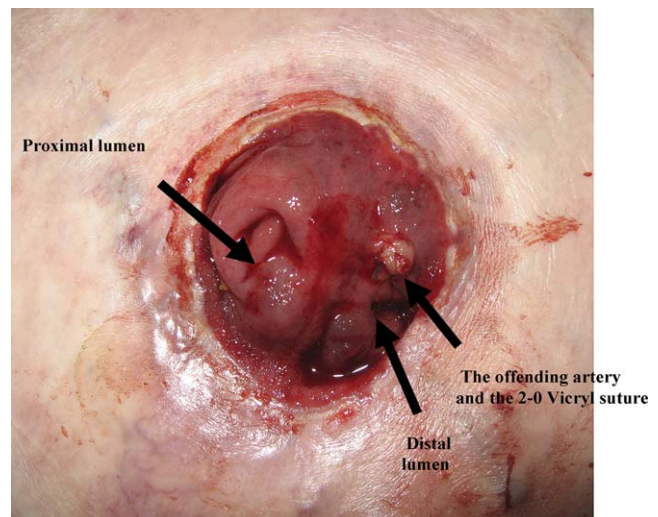


Figure 1

Reference

1. Duchesne JC, Wang YZ, Weintraub SL, Boyle M, Hunt JP. Stoma complications: a multivariate analysis. *Am Surg* 2002 Nov; 68(11):961–6.

Jayant S. Vaidya*

Faisal Alem

Fera Mansor

Department of Surgery and Molecular Oncology, Level 6,
Ninewells Hospital and Medical School, Dundee DD1 9SY, UK

*Corresponding author. Tel.: +44 1382 660 111.

E-mail address: j.s.vaidya@dundee.ac.uk (J.S. Vaidya)